

第 1 4 号

出典 : Dermatology、1997 ; 195 : 235-238 全文訳
小児の口周囲炎 : その臨床像、発病関連要因および外用メトロニ
ダゾール単剤の治療効果

抗炎症作用

Perioral Dermatitis in Children—Clinical Presentation, Pathogenesis-Related Factors and Response to Topical Metronidazole

Kerstin Boeck (ドイツ) Dermatology (1997) 195, 235~238

〔小児の Perioral Dermatitis : その臨床像、発病関連要因、及び外用メトロニダゾールの治療効果〕

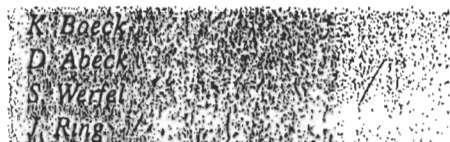背景 : Perioral dermatitis は若い女性に良く見られる皮膚疾患であるが、小児では稀である。

目的 : 小児の perioral dermatitis の臨床像について述べると共に、その病理発生の機作並びに外用メトロニダゾールの治療効果について述べる。

方法 : 4歳から12歳の女児4名、男児3名計7名について皮膚科学的検査と評価を行った。本試験に先行して実施されたステロイド療法についてはこれを記録した。全員に通常行われている aeroallergens 6種について皮膚ブリックテストを行った。また、全員について消化器系の *Candida albicans* のスクリーニングを実施した。薬剤 (市販の基剤にメトロニダゾールを溶解して調整) は、初めの2週間は1%剤 (1週目1日1回、2週目1日2回)、3週以降は2%剤 (1日2回) を患部に塗布した。

結果 : 7名中6名の患者は、当外来を受診する前に顔にステロイドの塗布を受けていたので、その病因としての可能性も否定は出来ない。アトピー或は消化器のカンジダ症の合併は1例も無かった。
皮膚の病変は3~6ヵ月後に全例で消失した。その後2年間観察したが再発例は無かった。

結論 : Perioral dermatitis は、小児において特異な部位に紅斑を伴う丘疹、丘疱疹の出現を特徴とする独立した疾患と考えるべきである。メトロニダゾールは、小児の perioral dermatitis に対して有効で安全な治療法であることが証明された。Perioral dermatitis の病理発生にアトピー或は消化器のカンジダ症は関連がないようである。



Department of Dermatology,
Technical University of Munich, Germany

Perioral Dermatitis in Children – Clinical Presentation, Pathogenesis-Related Factors and Response to Topical Metronidazole

Key Words

Perioral dermatitis
Children
Metronidazole

Abstract

Background: Perioral dermatitis, a common skin disorder in young women, is rarely described in children. **Objective:** This study elaborates the clinical features of perioral dermatitis in children as well as possible pathogenetic mechanisms and the response to topical metronidazole. **Methods:** Seven children (4 females, 3 males between 4 and 12 years of age) were evaluated and dermatological examination was carried out. Pretreatment with topical corticosteroids was documented. Skin prick test with a panel of six common aeroallergens was performed in all children. All children were screened for gastrointestinal colonization with *Candida albicans*. Patients were treated with topical metronidazole 1% during the first 2 weeks. From the 3rd week on 2% metronidazole was used. **Results:** In all but one child topical corticosteroids had been used in the face prior to the first presentation at our outpatient department suggesting a possible pathogenetic role. An association with atopy or intestinal candida colonization was not found. In all children skin lesions resolved after 3–6 months. The children remained free of symptoms over an observation period of 2 years. **Conclusion:** Perioral dermatitis has to be considered as differential diagnosis in children presenting with erythematous papules and papulovesicles in typical locations. Metronidazole proved to be effective and safe in the treatment of perioral dermatitis in children. Atopy and gastrointestinal colonization with *C. albicans* do not seem to play a role in the pathogenesis of perioral dermatitis.

Introduction

Perioral rosacea-like dermatitis is frequently reported in young women. Clinical features consist of erythematous papules and papulopustules usually localized in the perioral region [1, 2]. In children perioral dermatitis is rarely de-

scribed [3, 5–8]. As in adults an overuse of potent topical corticosteroids is often associated with the development of skin eruptions. Treatment can be time-consuming, because there is usually a relapse after discontinuation of corticosteroid therapy. Accepted treatment modalities include oral as well as topical erythromycin [9, 10] and topical metro-

KARGER

E-Mail karger@karger.ch
Fax +41 61 306 12 34
http://www.karger.ch

© 1997 S. Karger AG, Basel
1018-8665/97/1953-0235\$12.00/0

This article is also accessible online at:
http://BioMedNet.com/karger

Dr. med. Kerstin Boeck
Klinik und Poliklinik für Dermatologie und Allergologie
am Biederstein Technische Universität München
Biedersteinerstrasse 29, D-80802 München (Germany)
Tel. 89-38494, Fax 89-3849-3323

nidazole [3, 11] for the childhood form of perioral dermatitis. The oral administration of tetracycline is contraindicated in children.

We report 7 children with perioral dermatitis who were carefully examined concerning possible etiologic factors and treatment with a standardized treatment protocol for topical metronidazole.

Diagnostic and Clinical Investigations

Seven children (4 females, 3 males between 4 and 12 years of age) presented with facial erythematous papules and papulopustules with the typical appearance of perioral dermatitis within a period of 2 years (1991-93). Table 1 lists individual patients' data concerning localization of skin lesions, previous therapeutic approaches, findings from allergological and microbiological investigations as well as kind and duration of therapy.

In all but 1 child lesions were localized around the mouth with 5 children having additional lesions in other sites (perinasal in 4, periocular in 3). The duration of symptoms before presentation ranged between 2 and 7 months.

All but 1 child had been pretreated with topical corticosteroids of moderate to strong potency. Class 3 corticosteroids [12] had been used in 3 children. Two children had received mild corticosteroids. In 2 children hydrocortisone had been applied previously. Some children had received additional therapy with antibiotics before presentation.

Skin prick tests (SPT) using a panel of six common aeroallergens (house dust mite *Dermatophagoides pteronyssinus* (I and II, dog dander, cat dander, grass pollen and pollen allergen mixture, extracts: Allergopharma) were performed in all children and were negative in 6 of 8 children. The single sensitivity seen in 1 child was without clinical relevance. Stool samplings for the presence of *Candida albicans* which was performed for each child on 3 different occasions revealed a nonsignificant intestinal colonization with *C. albicans* ($<10^3$ CFU/g stool) in 2 children.

In all patients therapy was started with topical metronidazole 1% applied once daily for the 1st week. Metronidazole was incorporated in two commercially available oil-in-water emulsions with varying lipid concentrations and used according to individual skin sensitivity. During the 2nd week metronidazole 1% was used twice a day. From the 3rd week on treatment was performed with metronidazole 2% twice a day until resolution of skin lesions.

All children showed a slow but significant amelioration of skin lesions after 4-6 weeks of treatment. Time to complete restitution was between 3 and 6 months. Treatment




Fig. 1. Perioral dermatitis with perioral, perinasal and periocular distribution of skin lesions (patient No. 1).

was well tolerated without side effects. All patients remained clear of symptoms over an observation period of 2 years.

Discussion

The presented cases of perioral dermatitis in children illustrate the difficulties concerning the correct diagnosis. The clinical picture with grouped erythematous papules and papulopustules is very typical. A granulomatous variant of perioral dermatitis that shows a preference for black children has been described and has to be differentiated from sarcoidosis [6, 8]. In children skin lesions often show a perinasal and periocular distribution in addition to the clas-

Table 1. Individual data of children with perioral dermatitis included in the study

Patient No.	Age (yr)	Sex	Localization	Previous treatment with corticosteroids ¹	Previous treatment with antibiotics	Duration months	<i>C. albicans</i> CFU/g stool	SPT	Time to restitution months
1	4	M	perioral, perinasal, periocular	class 2	erythromycin (topical and systemic)	3	negative	negative	4
2	5	M	perioral	class 1	tetracycline (topical)	4	102	negative	3
3	7	F	perioral	class 3	fucidine acid (topical)	6	negative	negative	6
4	6	F	perioral, periocular	no	no	2	negative	cat dander	3
5	8	F	perioral, perinasal	class 2	tetracycline (topical) erythromycin (systemic)	2	101	negative	4
6	9	F	perioral, perinasal	class 3	tetracycline (topical)	3	negative	negative	3
7	10	M	perioral, perinasal, periocular	class 1	clindamycin (topical and systemic)	7	negative	negative	5

¹ According to classification of Niedner.

² Duration of symptoms until first consultation.

³ Intestinal colonization with *C. albicans*.

sical perioral site [3, 8]. In our series a minority of children (2 out of 7) had perioral lesions only. In addition 6 of them had lesions in other sites (perinasal in 4, periocular in 3 cases).

There are only a few reports of perioral dermatitis in children [3, 5-8]. In a large series of 203 cases only 15 children were described [4]. As in adults perioral dermatitis in childhood seems to prefer the female sex but the percentage of male patients (3 out of 8 patients in this series) seems to be higher than in adults. Our findings concerning the sex ratio are in agreement with other reports [3, 4, 8].

Among the suspected causes of perioral dermatitis the use of potent topical corticosteroids is the best documented [2, 3, 5, 13]. In the presented series 2 children had been pretreated with corticosteroids of class 3 (according to the classification of Niedner [12]). Two others had received a therapy with corticosteroids of class 2. In 2 children hydrocortisone had been used before. The role of hydrocortisone in the pathogenesis of perioral dermatitis is doubtful, because hydrocortisone proved to be a successful treatment in perioral dermatitis [3, 14]. We were not able to find an association of perioral dermatitis and gastrointestinal colonization with *C. albicans* in our patients. Negative SPT in 6 out of 7 children suggest that atopy does not predict a higher risk for suffering from perioral dermatitis.

The first step in therapeutic management should be the discontinuation of all topical corticosteroids, which, how-

ever, leads usually to a relapse of skin lesions. Oral tetracycline to prevent poststeroid flare is contraindicated in children younger than 11 years old. Therapeutic modalities suggested are topical application of erythromycin [9, 10] or metronidazole [11, 15]. The therapy with 0.75% metronidazole gel in adults and children with perioral dermatitis has been shown to be effective and safe. In the reported series metronidazole was used in a concentration of 1 respectively 2% in an oil-in-water emulsion according to individual skin sensitivity. Compared to previous reported cases by Manders and Lucky [3] time to restitution was significantly longer in our series. Significant amelioration was observed after 4-6 weeks of treatment. Time to restitution was 3-6 months. All children remained free of symptoms in the follow-up period.

Metronidazole proved to be safe. Side effects were not seen in our patients throughout the study. When topically applied only small amounts of metronidazole are absorbed [16]. Terato- and carcinogenicity could not be shown in humans [17]. The response of perioral dermatitis to metronidazole is rather the result of the drug's anti-inflammatory and immunosuppressive effects and not a direct antimicrobial action [16, 18].

References

- 1 Wilkinson D: What is perioral dermatitis? *Int J Dermatol* 1981;20:485-486.
- 2 Sneddon I: Perioral dermatitis. *Br J Dermatol* 1972;87:430-434.
- 3 Manders SM, Lucky AW: Perioral dermatitis in childhood. *J Am Acad Dermatol* 1992;27:688-692.
- 4 Wilkinson DS, Kirton V, Wilkinson JD: Perioral dermatitis: A 12-year review. *Br J Dermatol* 1979;101:245-257.
- 5 Savin JA, Alexander S, Marks R: A rosacea-like eruption of children. *Br J Dermatol* 1972;87:425.
- 6 Silevis Smitt JH, Das PK, Van Ginkel CJW: Granulomatous perioral dermatitis (facial Afro-Caribbean childhood eruption, FACE). *Br J Dermatol* 1991;125:399.
- 7 Gianotti F, Ermacora E, Benalli MG, et al: Particulière dermatitis peri-orale infantile: observation sur 5 cas. *Bull Soc Fr Dermatol Syphiligr* 1970;77:341.
- 8 Frieden IJ, Prose NS, Fletcher V, Turner ML: Granulomatous perioral dermatitis in children. *Arch Dermatol* 1989;125:369-373.
- 9 Coskey RJ: Perioral dermatitis. *Cutis* 1984;34:55-58.
- 10 Bikowski JB: Topical therapy for perioral dermatitis. *Cutis* 1983;31:678-682.
- 11 Velen NK, Munkvad JM, Nielsen AO, et al: Topical metronidazole in the treatment of perioral dermatitis. *J Am Acad Dermatol* 1991;87:425-429.
- 12 Niedner R: Kortikosteroide bei Hautkrankheiten - externe und systemische Anwendung. *Der Bay Int* 1993;13(4):3-11.
- 13 Cotterill JA: Perioral dermatitis. *Br J Dermatol* 1979;101:259-262.
- 14 Ellis CN, Stawiski MA: The treatment of perioral dermatitis, acne rosacea, and seborrheic dermatitis. *Med Clin North Am* 1982;66:819-830.
- 15 Miller SM, Shalita AR: Topical metronidazole gel (0.75%) for the treatment of perioral dermatitis in children. *J Am Acad Dermatol* 1994;31:847-848.
- 16 Schmadel LK, McEvoy GK: Topical metronidazole: a new therapy in rosacea. *Clin Pharm* 1990;9:94-101.
- 17 Roe FJC: Toxicologic evaluation of metronidazole with particular reference to carcinogenic, mutagenic and teratogenic potential. *Surgery* 1983;93:158-164.
- 18 Bleicher PA, Charles JH, Sober AJ: Topical metronidazole therapy for rosacea. *Arch Dermatol* 1987;123:609-614.